

PRENATAL EXCLUSION OF CROUZON SYNDROME BY MUTATION ANALYSIS OF *FGFR2*

Vorapong Phupong¹, Chalurmporn Srichomthong² and Vorasuk Shotelersuk²

¹Department of Obstetrics and Gynecology, ²Department of Pediatrics, Faculty of Medicine, Chulalongkorn University, Bangkok, Thailand

Abstract. Crouzon Syndrome is an autosomal dominant syndromic craniosynostosis characterized by premature closure of cranial sutures, exophthalmos, and midface hypoplasia. It is caused by multiple mutations in the *fibroblast growth factor receptor 2 (FGFR2)*. We describe prenatal genetic testing of *FGFR2* in a fetus of a mother whose previous child had Crouzon Syndrome due to an apparently *de novo* mutation, S351C. Sequence electropherograms of the exon 10 of *FGFR2* encompassing the codon 351 revealed only the normal sequence, thus predicting a very high likelihood of an unaffected fetus. The study was confirmed by the birth of a normal neonate. We report the use of molecular genetic testing to exclude Crouzon Syndrome due to *FGFR2* mutation prenatally. Prenatal diagnostic testing for a known mutation is a reasonable option for couples at risk for having a child with Crouzon Syndrome due to germline mosaicism. Molecular testing is more accurate and reliable than ultrasonography and provides families with reassurance.

INTRODUCTION

Crouzon Syndrome (MIM 123500) is an autosomal dominant syndromic craniosynostosis characterized by premature closure of cranial sutures, exophthalmos, and midface hypoplasia. The birth prevalence of Crouzon Syndrome is estimated to be 15-16 per 1,000,000 births (Cohen and Kreiborg, 1992) with 30-60% of cases being sporadic (Al-Qattan and Phillips, 1997). The majority of patients with Crouzon Syndrome have mutations in the extracellular immunoglobulin III domain of the *fibroblast growth factor receptors 2 (FGFR2)* gene (Passos-Bueno *et al*, 1999). Here, we describe prenatal genetic testing for *FGFR2* S351C mutation in a fetus of a mother whose previous child had died of Crouzon Syndrome.

MATERIALS AND METHODS

Case evaluation

A 33-year-old woman's first child was diagnosed with Crouzon Syndrome. The patient's de-

tailed clinical and molecular features were previously described (case 4 in Shotelersuk *et al*, 2003). Briefly, the child had a severe form of Crouzon Syndrome with hydrocephalus, compressive optic neuropathy, and hearing loss; died of aspiration pneumonia at the age of 1 year (Fig 1). Mutation analysis of *FGFR2* revealed an S531C mutation (Fig 2A), which was not present in her parents. The parents were counseled that their risk of having another child with Crouzon Syndrome was low since the mutation appeared to be *de novo*.

After extensive counselling about the low risk of recurrent Crouzon Syndrome in her second pregnancy, the couple chose to undergo prenatal diagnostic testing for the *FGFR2* mutation. Amniocentesis was performed at 16 weeks gestation without complications. The amniotic fluid was sent for mutation analysis and chromosome studies; no abnormalities were detected. Serial ultrasound examinations at 7, 18, 28, and 37 weeks gestation revealed normal anatomy and growth of the fetus.

At 38 weeks gestation, the patient delivered a normal appearing female infant by repeat cesarean section.

Mutation analysis

After informed consent was obtained, 10 ml

Correspondence: Dr Vorapong Phupong, Department of Obstetrics and Gynecology, Faculty of Medicine, Chulalongkorn University, Rama IV Road, Pathumwan, Bangkok 10330, Thailand.
Tel: 66 (0) 2256 4241; Fax: 66 (0) 2254 9292
E-mail: vorapong.p@chula.ac.th

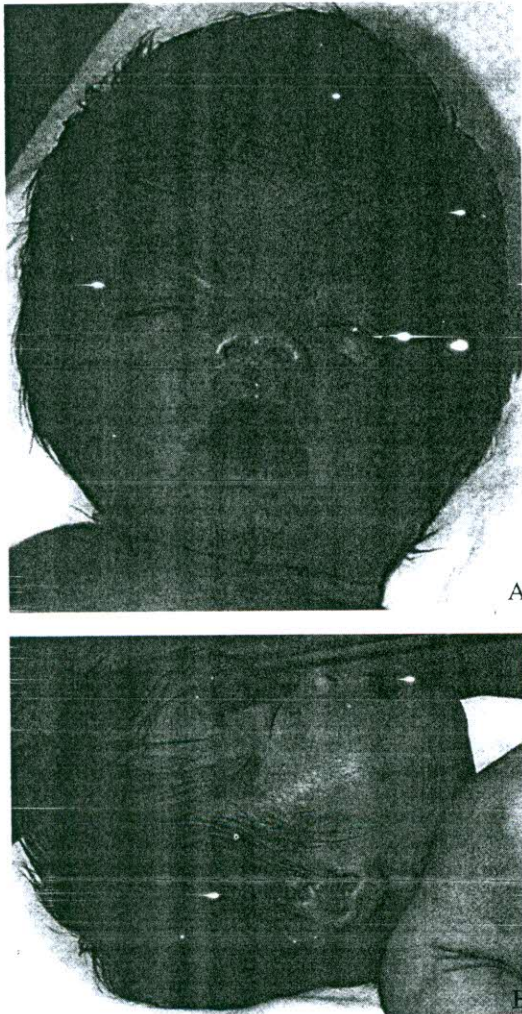

Fig 1—The affected child with Crouzon Syndrome had frontal bossing, proptosis, and maxillary hypoplasia.

of amniotic fluid was aspirated and used for DNA isolation by a QIAamp® DNA Mini Kit (QIAGEN, Valencia, CA, USA). The *FGFR2* exon 10 was amplified using previously described methods (Shotelersuk *et al*, 2002). The PCR product was then sent for direct sequencing at the National Science and Technology Development Agency, Bangkok, Thailand.

RESULT AND DISCUSSION

Sequence electropherograms revealed only a normal sequence (Fig 2B). Crouzon Syndrome

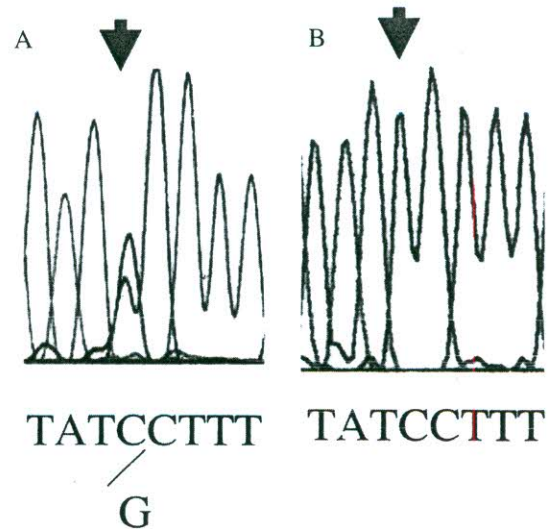


Fig 2—The sense sequence electropherograms in the affected previous child (A) and the unaffected fetus (B). The arrows show that the wild-type sequence, C, can be observed along with the mutant sequence, G, in the affected girl but only the wild-type sequence in the unaffected.

is an autosomal dominant condition but can occur sporadically as a result of a *de novo* mutation in *FGFR2*. The majority of Thai patients with Crouzon Syndrome are sporadic (Shotelersuk *et al*, 2003) and hence, the risk of having another child with the same syndrome is low for these parents. Nonetheless, because of gonadal mosaicism, the recurrence risk of an autosomal dominant condition in the siblings of a child with the disorder with unaffected parents does exist. The risk varies from condition to condition (Zlotogora, 1998). It appears to be approximately 6% for osteogenesis imperfecta type II (Byers *et al*, 1988) but only 0.02% for achondroplasia (Mettler and Fraser, 2000). The risk for Crouzon Syndrome has not been measured.

The first child had a clinically severe form of Crouzon Syndrome. She died at the age of 1 year, though many Crouzon patients live into adulthood. The severity was the main factor influencing the parents' decisions during the subsequent pregnancy. Despite a low recurrence risk, they decided to undergo prenatal diagnostic testing for the *FGFR2* mutation. The couple elected amniocentesis over chorionic villus sampling (CVS) due to the lower risk of fetal loss.

Other procedures have been utilized to diagnose Crouzon Syndrome antenatally. Prenatal ultrasonographic features of exophthalmos (Menashe *et al*, 1989), binocular diameter (Leo *et al*, 1991) and unusual head shape (bossing of the forehead, splaying of the coronal sutures) (Brook, 1986; David *et al*, 1991) were described for the diagnosis of Crouzon Syndrome. However, these findings can be equivocal (Chen *et al*, 2003). DNA-based testing for a known mutation is more accurate and reliable. Alternatively, a couple at high risk for having a child with Crouzon Syndrome may consider preimplantation genetic diagnosis (PGD). There was a report of pregnancy following PGD for Crouzon Syndrome (Abou-Sleiman *et al*. 2002). However, PGD requires very sophisticated techniques including single cell PCR and is expensive. Since neither parent is a carrier of the *FGFR2* mutation, they chose to use prenatal molecular testing.

Conclusions

We report the use of prenatal molecular testing for Crouzon Syndrome. Prenatal diagnostic testing for a known mutation is a reasonable option for couples at risk for having a child with Crouzon Syndrome due to germline mosaicism. Molecular testing is more accurate and reliable than ultrasonography and provides families with reassurance.

ACKNOWLEDGEMENTS

This work was supported by Development Grants for New Faculty/Researchers, Chulalongkorn University and the Thailand Research Fund (Contract grant number: RSA/05/2544).

REFERENCES

- Abou-Sleiman PM, Apeessos A, Harper JC, Serhal P, Delhanty JD. Pregnancy following preimplantation genetic diagnosis for Crouzon Syndrome. *Mol Hum Reprod* 2002; 8: 304-9.
- Al-Qattan MM, Phillips JH. Clinical features of Crouzon's Syndrome patients with and without a positive family history of Crouzon's Syndrome. *J Craniomaxillofac Surg* 1997; 8: 11-3.
- Brook F. Sonographic appearance of craniofacial dysostosis in utero. *Radiography* 1986; 52: 153-4.
- Byers PH, Tsipouras P, Bonadio JF, Starman BJ, Schwartz RC. Perinatal lethal osteogenesis imperfecta (OI type II): a biochemically heterogeneous disorder usually due to new mutations in the genes for type I collagen. *Am J Hum Genet* 1988; 42: 237-48.
- Chen CP, Chern SR, Lin SP, Wang W, Tsai FJ. Prenatal identification of a G338E mutation in *FGFR2* in a fetus without sonographic appearance of craniosynostosis. *Prenat Diagn* 2003; 23: 175-6.
- Cohen MM Jr, Kreiborg S. Birth prevalence studies of the Crouzon Syndrome: comparison of direct and indirect methods. *Clin Genet* 1992; 41: 12-5.
- David DJ, Cooter RD, Edwards TJ. Crouzon twins with cloverleaf skull malformations. *J Craniomaxillofac Surg* 1991; 2: 56-60; discussion 1.
- Leo MV, Suslak L, C. Mesh VL, Adhate A, Apuzzio JJ. Crouzon Syndrome: prenatal ultrasound diagnosis by binocular diameters. *Obstet Gynecol* 1991; 78: 906-8.
- Menashe Y, Ben Baruch G, Rabinovitch O, Shalev Y, Katzenelson MB, Shalev E. Exophthalmos—prenatal ultrasonic features for diagnosis of Crouzon Syndrome. *Prenat Diagn* 1989; 9: 805-8.
- Mettler G, Fraser FC. Recurrence risk for sibs of children with "sporadic" achondroplasia. *Am J Med Genet* 2000; 90: 250-1.
- Passos-Bueno MR, Wilcox WR, Jabs EW, Sertie AL, Alonso LG, Kitoh H. Clinical spectrum of fibroblast growth factor receptor mutations. *Hum Mutat* 1999; 14: 115-25.
- Shotelersuk V, Ittiwut C, Srivuthana S, Mahatumarat C, Lerdlum S, Wacharasindhu S. Distinct craniofacial-skeletal-dermatological dysplasia in a patient with W290C mutation in *FGFR2*. *Am J Med Genet* 2002; 113: 4-8.
- Shotelersuk V, Mahatumarat C, Ittiwut C, *et al*. *FGFR2* Mutations among Thai children with Crouzon and Apert Syndromes. *J Craniomaxillofac Surg* 2003; 14: 101-4.
- Zlotogora J. Germ line mosaicism. *Hum Genet* 1998; 102: 381-6.